



THE EVALUATION OF HEMATOLOGICAL, BIOCHEMICAL AND IMMUNOLOGICAL PARAMETERS IN IRAQI PATIENTS INFECTED WITH HYDATID CYST

Nisreen shaker Mahmoud¹, Ekhlās M. Idan², Muhanned K Ali³

¹Department of Biology, College of Science for Women, University of Baghdad, Baghdad, Iraq, nesreen.saleh2102p@csu.uobaghdad.edu.iq.

²Assistant Professor PhD. Department of Biology, College of Science for Women, University of Baghdad, Baghdad, Iraq, ekhlasmeh_bio@csu.uobaghdad.edu.iq.

³Surgeon PhD. Board, Department of Thoracic and Vascular Surgery Ghazi AL-Hariri Subspecialty Surgical Hospital, Baghdad, Iraq, muhanned.kareem1982@gmail.com.

Received 25/ 2/ 2024, Accepted 10/ 6/ 2024, Published 31/ 12/ 2025

This work is licensed under a CCBY 4.0 <https://creativecommons.org/licenses/by/4.0>



ABSTRACT

Cystic echinococcosis (CE) is an endemic disease that causes serious disease and economic loss in the majority of countries around the world. The aim of the present study was to determine the effects of disease on some haematological, biochemical and immunological parameters in Iraqi patients with hydatid cyst. The study included 50 CE patients which their samples were collected from several hospitals in Baghdad, Iraq, for CE removal surgery and 50 healthy controls. The serum was collected from January 2022 to June 2023. The patients group ranged in age was 20–55 years. Rural patients were infected at a higher rate than urban patients (58.00% and 42.00%, respectively), The lung was the most affected organ (74.00%), followed by the liver (18.00%), then the liver and lung together (8.00%). CE patients had significantly higher in number of white blood cell WBC than control group members (11.54 ± 0.23 and 7.87 ± 0.27 , respectively). Also the levels of haemoglobin (Hb); packed cell volume (PCV), and erythrocyte sedimentation rate ESR were elevated in patients with hydatid cyst (11.84 ± 0.18 mg/ml; 37.49 ± 0.58 mg/dl, and 30.17 ± 1.23 respectively) compared to individuals in the control group (13.60 ± 0.16 ; 42.90 ± 0.48 , and 8.90 ± 0.91 respectively). They also found higher levels of C-reactive protein (CRP) 33.33% of patients with hydatid cysts. Upon evaluating liver function in patients with CE, it was observed that there were elevated levels of aspartate aminotransferase (AST) and alanine aminotransferase (ALT) (27.86 U/L and 32.74 U/L respectively) compared to individuals in the control group. The results demonstrated that the concentration of TNF- α in the serum of patients with CE was no significant ($P < 0.05$) compared to that of the controls group (154.44 ± 10.66 ng/L and 139.58 ± 7.64 ng/L respectively). Conclusion: to our findings, the present study has explained that the infection with hydatid disease affects haematological and liver function after examination of some biochemicals related to liver function and immunological parameters. This may interfere with their immune system's inflammatory response and contribute to the pathogenesis of CE.

Keywords: Cystic echinococcosis, C-reactive protein, hematological, Liver functions.



تقييم المؤشرات الدموية والكيميائية الحيوية والمناعية لدى المرضى العراقيين المصابين بالاكياس العذرية

نسرين شاكر محمود¹, اخلاص مشرف عيدان², مهدي كريم علي³¹قسم علوم الحياة، كلية العلوم للبنات، جامعة بغداد، بغداد، العراق. nesreen.saleh2102p@csu.uobaghdad.edu.iq.²استاذ مساعد دكتور، قسم علوم الحياة، كلية العلوم للبنات، جامعة بغداد، بغداد، العراق. ekhlasmeh bio@csu.uobaghdad.edu.iq.³طبيب جراح بورد (دكتوراه)، قسم جراحة الصدر والاعوية الدموية، مستشفى غازي الحريري، بغداد، العراق. muhanned.kareem1982@gmail.com.

الخلاصة

يعد داء المشوكات الكيسي (CE) من الامراض المتوطنة الخطيرة حيث انه يسبب خسائر اقتصادية في معظم بلدان العالم. الهدف من هذه الدراسة هو تحديد التأثيرات السلبية للمرض على بعض المعايير الدموية والكيميائية الحيوية والمناعية لدى المرضى العراقيين الذين يعانون من الاكياس العذرية. شملت الدراسة 50 مريضاً بالمشوكات تم إدخالهم إلى مستشفى غازي الحريري في بغداد، العراق، لغرض اجراء جراحة لإزالة الكيس و50 عينة من الأصحاء كمجموعة سيطرة. جمع المصل في الفترة من يناير 2022 إلى يونيو 2023، و خزنت جميع العينات لحين استخدامها. تراوح عمر العينات مابين 20-55 سنة. معظم المصابين من المناطق الريفية مقارنة بالمناطق الحضر (58.00% و 42.00% على التوالي)، وشكلت الرئة أكثر الأعضاء إصابة (74.00%)، يليها الكبد (18.00%)، ثم الكبد والرئة معاً (8.00%). أظهرت النتائج بارتفاع خلايا الدم البيضاء WBC لدى مرضى CE بالموازنة مع مجموعة السيطرة (11.54 ± 0.23 و 7.87 ± 0.27 على التوالي). ولوحظ أيضاً ارتفاع بمستويات الهيموجلوبين (Hb) وحجم الخلايا المعبأة (PCV)، ومعدل ترسيب كرات الدم الحمراء (ESR) في مرضى المشوكات الكيسية (11.84 ± 0.18 mg/ml و 37.49 ± 0.58 mg/dl، و 30.17 ± 1.23 على التوالي) مقارنة بمجموعة السيطرة (13.60 ± 0.16 و 42.90 ± 0.48 و 8.90 ± 0.91 على التوالي). كذلك لوحظ ارتفاع بروتين سي التفاعلي (CRP) في المرضى المصابين بالاكياس العذرية وعند تقييم وظائف الكبد لدى مرضى CE، لوحظ أن هناك مستويات مرتفعة من ناقلة أمين الأسبارتات (AST) وناقلة أمين الألانين (ALT) (27.86 وحدة / لتر و 32.74 وحدة / لتر على التوالي) مقارنة بمجموعة الأصحاء. كذلك أظهرت النتائج بأن تركيز عامل التنخر الورمي الفاي- α TNF في مصل مرضى CE لم يكن مغنوباً ($P < 0.05$) مقارنة بتركيز الأصحاء (10.66 ± 154.44 ng/L و 7.64 ± 139.58 ng/L على التوالي). الاستنتاج: وفقاً للنتائج التي توصلت إليها الدراسة، فقد اوضحت الدراسة الحالية بأن الإصابة بالاكياس العذرية يؤثر على المعايير الدموية والكيميائية الحيوية المتعلقة بوظائف الكبد فضلاً على المعايير المناعية وهذا قد يتداخل مع الاستجابة الالتهابية لجهاز المناعي لدى المرضى مما يسهم في التسبب في مرض CE.

الكلمات المفتاحية: داء المشوكات الكيسي. بروتين سي التفاعلي؛ وظائف الكبد والدم.

INTRODUCTION

Cystic echinococcosis is a common parasitic disease caused by the infection of larval-stage tapeworm metacestodes of *Echinococcus granulosus* (Pakala et al., 2016). According to data published from different geographical areas, CE is acknowledged as a notable public health concern (Nasrieh et al., 2003; AL-Shanawi et al., 2012; Abdul Rasool et al., 2012; Zhang et al., 2015). As an indigenous disease, it causes both social and economic harm to countries. Each year, this disease causes the death of around 1 million people globally and incurs a financial burden of around \$3 billion dolar, including costs associated with treatment and livestock (Pakala et al., 2016).

The World Health Organization (WHO) records that over 100,000 individuals worldwide contract this disease annually (Romig, 2003). It is prevalent among rural communities in underdeveloped nations due to their frequent contact with domestic and wild animals (Salama et al., 2014).

CE typically arises from the inadvertent ingestion of *E. granulosus* eggs by humans and intermediate hosts. The hydatid cysts form as fluid-filled sacs within the host's internal organs as a result of the immunological response. The cysts consist of two layers derived from



parasites: an inner layer consisting of nucleated germinal cells and an outer layer devoid of cells formed of a laminated structure. The host envelops them within a fibrous capsule. (Zhang *et al.*, 2015). The manifestation of this disease encompasses a wide array of symptoms, which are contingent upon factors such as the size and placement of the cysts within the affected organ, the complications arising from cyst rupture, and the immune system's reaction (Torcal *et al.*, 1996). The immune response of the intermediate host is crucial in facilitating contact between the host and the parasite. The excretory chemicals of the parasite impact the immune-competent cells of humans. Parasites have evolved several strategies to evade the immunological responses of their hosts, ensuring their own survival and establishing chronic infections. In CE, there is a persistent chronic infection characterized by the presence of detectable humoral and cellular immune responses against the parasite (Siracusano *et al.*, 2012). *E. granulosus* strategically releases compounds that directly manipulate the immune responses of the host, promoting a robust anti-inflammatory reaction in order to effectively establish infection and ensure its survival within the host (Chandrasekhar & Parija, 2009). So that the aim of the present study was to determine the effects of disease on some haematological, biochemical and Immunological parameters in Iraqi patients with hydatid cyst

MATERIALS AND METHODS

Sample collection.

One hundred Iraqi participants were divided into two groups: 50 patients with hydatid cysts and 50 healthy controls. The control group consisted of individuals who were in good health, as indicated by normal levels of C-reactive protein (CRP) and Erythrocyte Sedimentation Rate (ESR). Patients diagnosed with hydatid cysts were chosen for surgical extraction following their visiting hospitals were (Ghazi Hariri Surgical Specialties, Gastroenterology and Hepatology Teaching Hospital, Medical City, and Baghdad Teaching Hospital) that gathered patients with CE throughout the timeframe of September 2022 to June 2023 and blood samples were taken from them. The infection was diagnosed utilizing diverse imaging modalities, such as ultrasound (US) or computed tomography (CT), which are the foremost techniques employed in diagnosis.

Examination of fertility cyst

There are two methods for conducting the CE examination. One method involves using radiography to identify calcification on an X-ray or CT scan, which typically indicates a state of inactivity. The second procedure entails surgically removing CE cysts from either the liver or lung tissue. Afterward, the surface of the cysts is purified using a solution of 70% ethanol. The cyst fluid was collected using a disposable syringe and subsequently analyzed at a macroscopic level. Turbidity in the cyst fluid suggests the cyst's ability to reproduce. To improve the precision of the results, a microscopic examination was performed on the fluid of cystic echinococcosis (CE) to confirm the presence of protoscoleces.

Blood collection

Blood samples were collected using a 5-ml syringe from the veins of each participant (both controls and patients) involved in this study. The blood was obtained through a vein puncture and was divided about equally. A volume of 2.5 millilitres of blood was added to a



tube containing ethylene diamine tetraacetic acid (EDTA) in order to measure the concentrations of (Hb), total white blood cell (WBC) count, packed cell volume (PCV), and erythrocyte sedimentation rate (ESR). The second tube contained 2.5 ml of blood was stored without any anticoagulant. This tube was used to determine the levels of aspartate aminotransferase (AST), alanine aminotransferase (ALT), C-reactive protein (CRP), and TNF- α . The tube was held at -20°C until the assay was conducted.

Blood parameters

Blood parameters which includes WBC, PCV, Hb were counted by the use of the hematological analyzer system (coulter differential analyzer) while ESR was determined by the Westergren assay method. (Ng, 1997).

C-reactive protein (CRP)

The CRP-latex test uses slide agglutination to detect CRP in human serum that is (a special type of protein produced by the liver in response to inflammatory cytokines) in a qualitative and semi-quantitative manner.

Liver functions test:

AST and ALT activity was used to determine the functional status of the liver (Schumann *et al.*, 2002)

Evaluation of TNF- α serum level

The levels of TNF- α in the serum of patients with CE and the control group were assessed using a sandwich Enzyme-Linked Immunosorbent Assay (ELISA). Commercially available kits from the Bioassay Technology Laboratory in China were utilized for this purpose.

Statistical Analysis:

The Statistical Analysis System- SAS (2018) program was used to detect the effect of difference groups (patients and control) in study parameters. T-test was used to significant compare between means. Chi-square test was used to significant compare between percentage (0.05 and 0.01 probability).

RESULTS

Out of the 50 patients diagnosed with CE, 31 (62%) were females and 19 (38%) were males. The patients' ages varied from 20 to 55, with a mean of 33.85 ± 1.96 . The control group comprised 10 (20%) females and 40 (80%) males. Furthermore, 21 individuals (42%) resided in urban regions, whereas 29 (58%) resided in rural regions. Based on the analysis of fertile cysts, 42 (84%) were found to be active, while 8 (16%) of the patients had non-fertile cysts. Furthermore, 37 (74%) patients had CE in their lung tissue, whereas 9 (18%) patients had CE in their liver. Additionally, 4 (8%) patients had CE in both their lung and liver, as indicated in Table 1.

**Table (1):** General characteristics of the studied groups.

Parameters	Groups		P value
	Control (N=50)	Patients (N=50)	
Age (year)	33.85 ±1.96	33.79± 2.36	0.98
<20 year	6 (12.00%)	9 (18.00%)	0.73
21-30	22 (44.00%)	17 (34.00%)	
31-40	6 (12.00%)	8 (16.00%)	
41-50	10 (20.00%)	8 (16.00%)	
>50 year	6 (12.00%)	8 (16.00%)	
Gender			0.00*
Male	40 (80.00%)	19 (38.00%)	
Female	10 (20.00%)	31 (62.00%)	
Residence			—
Rural	20 (40%)	29 (58.00%)	
Urban	30 (60%)	21 (42.00%)	
Cyst location			—
Lung	—	37 (74.00%)	
Liver	—	9 (18.00%)	
Lung & liver	—	4 (8.00%)	
Cyst			—
Fertile	—	42 (84.00%)	
Non-fertile	—	8 (16.00%)	

Hematological Manifestations

Complete Blood Count

The current study found that (WBC), (PCV), (Hb) and (ESR) averages were significantly higher in the patient group except for (PCV, Hb), it recorded a slight decline (11.54 WBC, 37.49 PCV 11.84 Hb and 30.17 ESR) compared to the control group (7.87 WBC, 42.90 PCV, 13.60 Hb, and 8.90 ESR) (Table 2).

**Table (2):** Comparison between patients with hydatid cyst and control in CBC.

Group	Mean \pm SE			
	W.B.C $\times 10^9/L$ / L	PCV (%)	Hb (g/dl)	ESR (mm/hour)
Patients	11.54 \pm 0.23	37.49 \pm 0.58	11.84 \pm 0.18	30.17 \pm 1.23
Control	7.87 \pm 0.27	42.90 \pm 0.48	13.60 \pm 0.16	8.90 \pm 0.91
T-test	0.713 **	1.625 **	0.515 **	3.356 **
P-value	0.0001	0.0001	0.0001	0.0001
** (P \leq 0.01).				

Serological parameters

C - reactive protein

The results about (CRP) showed non-significant values, the positive percentage in 17 patients was (33.33%) and the negative was 33 (66.67%). While it is not expressed in the healthy group (0.00%) as in Table 3.

Table (3): The percentage of C - reactive protein in patients and control groups.

Group	No	Positive+ No. (%)	Negative- No. (%)	P-value
Patients	50	17 (33.33%)	33 (66.67%)	0.302 NS
Control	50	0 (0.00%)	50 (100%)	0.0001 **
P-value	--	0.0001 **	0.0037 **	---
** Highly significant at (P \leq 0.01) , NS: Non-Significant.				

Liver functions test:

The biochemical parameters of each of the patients and the control group were investigated. Table (4) showed that the concentrations of AST and ALT in blood were increased after the infection with hydatid disease recording 27.86 of AST level and 32.74 of ALT level in the patients group compared with the control group (26.20 and 22.69 respectively).



Table (4): Comparison between the values of ALT and AST between the group of patients with CE and the control group.

Group	Mean \pm SE	
	ALT (U/L)	AST (U/L)
Patients	32.74 \pm 1.73	27.86 \pm 1.24
Control	22.69 \pm 0.79	26.20 \pm 1.22
T-test	4.415 **	3.624 NS
P-value	0.0001	0.364
** Highly Significant ($P \leq 0.01$)		** ($P \leq 0.01$).

Serum Level Tumor necrosis factor alpha, (TNF- α) level

The results demonstrated that the concentration of TNF- α in the serum of patients with CE was no significant ($P < 0.05$) compared to that of the control group. As shown in Figure 1, the mean serum level of TNF- α in patients was 154.44 ± 10.66 ng/L, compared to 139.58 ± 7.64 ng/L in the control group, as shown in Figure 1.

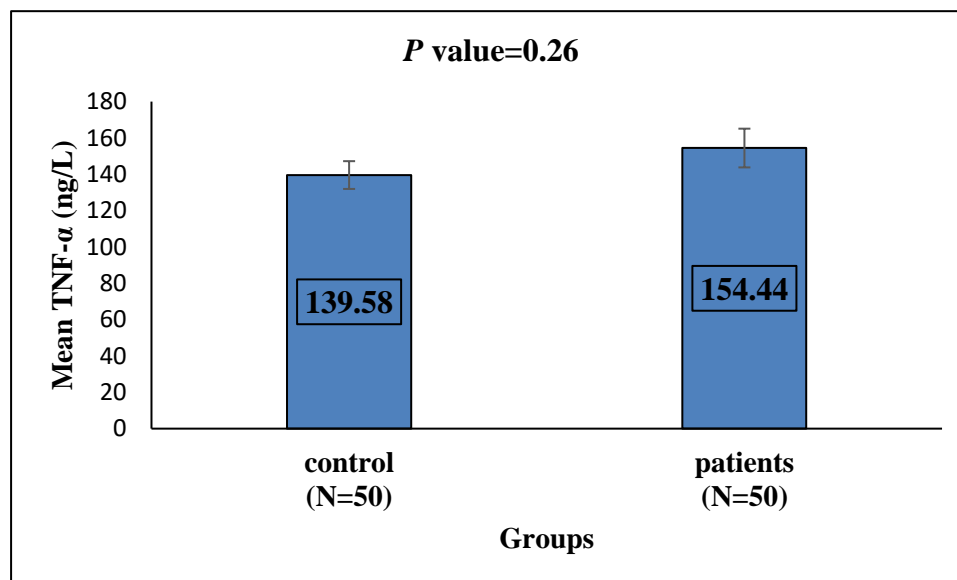


Figure (1): Levels of TNF- α in the control and patient groups.

DISCUSSION

CE is a persistent and long-lasting parasitic disease resulting from the larval forms of *E. granulosus* sensu lato (*E. granulosus* s.l.) (Mousavi *et al.*, 2020). Humans inadvertently serve as intermediary hosts. *E. granulosus* exhibits a global distribution, with an estimated minimum of 50 million individuals believed to be afflicted with cystic echinococcosis CE.



The study found a statistically significant increase ($P < 0.01$) in the white blood cell (WBC) count of patients compared to the control group (11.54 ± 0.23 cell $\times 10^9/L$ vs. 7.87 ± 0.27 cell $\times 10^9/L$). Patients with CE had a significantly lower hemoglobin level compared to the control group, with a mean $\pm SE$ level of 11.84 ± 0.18 g/dL in patients and 13.60 ± 0.16 g/dL in controls. Actually, haematological disorders are common in CE patients and can be considered a symptom or a sign of the disease. The findings were consistent with the research conducted by (Al-Nasiri, 2006; Moraitaki *et al.*, 2010; Al-Mobarak, 2006), all of whom observed an elevation in the quantity of (WBC). An increase in the number of (WBC) was observed in the present study, indicating a protective response to inflammatory processes in the body, especially in the liver, spleen, and kidneys. Inflammation triggers the bone marrow to create a significant amount of WBC. The elevation in white blood cell count may be attributed to the prolonged duration of the illness. (Nguyen & Diamond, 2000) explained that the production of white blood cells (WBC) is caused by parasites being able to get into the tissue. This is similar to what found (Al-Humairy, 2010).

In current study assessed PCV and Hb levels, which showed minimal variations between patients with CE and healthy control groups. These parameters remained within the normal range, consistent with the findings of Al-Mobarak (2006) and Moraitaki *et al.* (2010). The study demonstrated a statistically significant increase ($P < 0.01$) in the erythrocyte sedimentation rate (ESR) of patients compared to the healthy control group (30.17 ± 1.23 mm/hr and 8.90 ± 0.91 mm/hr, respectively). The Erythrocyte Sedimentation Rate (ESR) is an indirect and nonspecific technique used to measure total body inflammation (Maki *et al.*, 2021). Actually, the ESR is a routine haematological test that can show elevated levels of infections, cancer, and autoimmune illnesses (Tishkowski & Gupta, 2023). Another study demonstrates a substantial correlation between elevated levels of ESR and an increased occurrence of postoperative problems. (Ahmadinejad *et al.*, 2020).

Furthermore, our study revealed a rise in patients' CRP levels in comparison to the healthy control group, as shown in Table 3. This is consistent with in a study involving 28 patients with cystic echinococcosis, researchers found a diagnostically significant increase in CRP levels (Refik *et al.*, 2005, Alobadi, 2020). Habiloglu *et al.* (2019) discovered that 39.4% of the 40 patients with *Echinococcosis* caused by *E. alveolaris* showed an increase in CRP levels. Also Sura, (2013) reported a rise in C-reactive protein (CRP) levels in 14% of the 20 patients with liver cystic echinococcosis. The study revealed a 33% rise in CRP levels among patients with CE. Patients with CE exhibited a heightened inflammatory response, which was attributed to the observed outcome. In addition, a separate investigation revealed that the CRP level had been raised to 85 mg/L. Furthermore, the abdominal computed tomography scan demonstrated the presence of many cystic masses with thin walls and a uniform fluid density within the liver. Habiloglu *et al.* (2019). Hammami *et al.* (2015) conducted the study by observing an elevated level of C-reactive protein (CRP) in 14% of patients with hydatid cysts before surgery, indicating the presence of infection. However, after surgical excision, the mean level of CRP fell to 4% within 15 days. The study conducted by Refik *et al.* (2005) showed a significant increase in serum CRP levels in patients with cystic echinococcosis, which aligns with our findings. In addition, the study observed that these levels returned to normal three months after the operation. When trauma, inflammation, or infection occurs, CRP levels quickly increase, and they decrease just as swiftly when the disease is resolved (Sura, 2013).

The present study observed a notable elevation in the average levels of liver enzymes (AST and ALT) in the bloodstream following infection with hydatid cyst illness in the lungs



and liver, surpassing the normal range. This finding corroborated the findings provided by **Izadi & Ajami (2006)**, who documented the levels of ALT and AST in animals and humans infected with hydatid cyst illness. Consistent with **Abdullah (2007)** findings, which indicate that liver infection with cestoda tapeworms causes hepatocyte death and enzyme release, resulting in elevated levels of AST. The researchers discovered that it is recommended to regularly monitor the aminotransferase enzyme levels throughout the infection and therapy with albendazole (**Shindala et al., 2007**). In a separate study conducted by **Yakhchali et al., 2017**, it was observed that the host tissues in contact with hydatid had the highest levels of activity for AST and ALT. Hydatid cysts, being space-occupying formations, impose pressure on the adjacent tissues, resulting in tissue destruction and the release of enzymes from the injured cells into the surrounding tissue. The immune response to *E. granulosus* is characterised by the simultaneous presence of both Th1 and Th2 responses. Early activation of Th1 cells contributes to the establishment of immunological protection in the host, while activation of Th2 cells is linked to the progression of the chronic stage of *E. granulosus* infection (**Dorosti et al., 2016; Siracusano et al., 2012**). Hence, it is commonly acknowledged that in most cases of parasitic infections, an immune response of either Th1 or Th2 nature has the ability to regulate and manage the illness. The transition from a Th2-type immune response to a Th1-type immune response appears to be crucial for the formation of a defensive phenotype. The vulnerability or immunity in some parasite infections is linked to the presence or absence of Th1- or Th2-type reactions. In these cases, a distinct cytokine response is crucial, as highlighted by **Jankovic et al. (2001)**. **Mezioug & Touil-Boukoffa (2009)** found that the clinical stage of the disease, the location of the cysts, and the type of treatment, whether it is pharmaceutical or surgical, influence the production of cytokines. Also, according to the present study, no significant differences were observed for individuals with CE in serum TNF- α levels compared with healthy subjects. Multiple papers detail the role of innate TNF- α -dependent processes in driving cell-mediated immunity through the activation of CD4+ and CD8+ T cells. TNF- α , along with other cytokines including IL-12 and IFN- γ , is crucial in the initial management of the infection. The cytokines play a crucial role in facilitating the formation of a potent CD4+ Th1 response, which is essential for managing the infection and resolving the illness caused by the *L. donovani* infection (**Gainavaram et al., 2016**).

In their study, Abo-Aziza et al., found that calves infected with Hydatid displayed a significantly elevated serum level of Th-1 pro-inflammatory cytokines, specifically TNF- α and IL-6, compared to non-infected cattle. Nevertheless, the blood level of Th-2 anti-inflammatory cytokines (IL-4 and IL-10) was markedly lower ($p < 0.05$) in infected calves compared to non-infected ones. The data showed that the levels of Th1-polarized cytokines (TNF- α and IL-6) in the serum were considerably greater ($p < 0.05$) in hydatid-infected camels compared to non-infected camels. The study conducted by **Abo-Aziza et al., 2020**. Additionally, a separate investigation revealed that the echinococcal infection has the ability to either enhance or inhibit immunological responses, which endure and thrive over an extended period in their mammalian hosts (**Ahlberg, 2012**). In the present investigation, the serum concentrations of Th-1 pro-inflammatory cytokines, specifically TNF- α , were found to be a slight and insignificant elevated in infected individuals compared to non-infected individuals. These findings align with the results of (**Rostami-Rad et al., 2018**), which demonstrated an initial rise in Th1-type cytokines and a decline in Th2-type cytokines following protoscoleces inoculation in mice during the early stages of infection. So the conclusion of the study indicated that the hydatid cysts require the development of more sensitive approaches for



diagnostics, as there are no obvious clinical symptoms and the immune response to larval antigens is minimal. Ultimately, the study concluded that assessing hematological, serological, and biochemical findings collectively is advantageous for diagnosis. Furthermore, diverse training programs should educate the public about the hydatid cyst, which continues to pose a significant public health issue in our region.

Acknowledgements We would like to express our appreciation to the patients, volunteers, and staff who participated in this study. For their assistance with sample collection, hospitals such as Ghazi al-Hariri Surgical Specialties, the Gastroenterology and Hepatology Teaching Hospital, Medical City, and Baghdad Teaching Hospital were contacted.

Ethical approval Ethical approval was obtained from the University of Baghdad, College of Science for Women (approval number 22/1) in cooperation with the Ministry of Health, (approval number 1618)

Author contribution NSM; Collected sample, prepared and wrote the manuscript, drew figures, and created tables; EMI. Supervised, planned, oversaw project administration, and reviewed and edited the manuscript. MA contributed through the diagnoses of CE patients, and reviewed and edited the manuscript.

Conflict of interest the authors declare no competing interests.

CONCLUSION

To our findings, the present study has explained that the infection with hydatid disease affects haematological and liver function after examination of some biochemicals related to liver function and immunological parameters. This may interfere with their immune system's inflammatory response and contribute to the pathogenesis of CE.

REFERENCES:

1. Abo-Aziza, F.A.M., Hendawy, S.H.M., Oda, S.S., Aboelsoued, D., & El Shanawany, E.E. (2020). Cell-mediated and humoral immune profile to hydatidosis among naturally infected farm animals. *Veterinary World*, 13(1), 214-221.
2. Abdullah, B.H. (2007). *Some Helminths Parasitized on Stray Cats Felis catus L. in Basrah and Epizootiological and Biological Studies on Taenia taeniaeformis Batsch*. 1786, Ph.D. Thesis, College of Education, University of Basrah.Iraq..
3. Alobadi, E.G.Y. (2020). Study of Some Immunological Parameters in Patient That Infected With Streptococcus pyogenes: Study of Some Immunological Parameters in Patient That Infected With Streptococcus pyogenes. (2020). *Iraqi Journal of Market Research and Consumer Protection*, 12(1), 128-132.
4. Al – Humairy, A. KH. (2010). *Evaluation of the Activity Datura stramonium Seeds Extracts on Growth and Development of Hydatid Cysts for Echinococcus granulosus in White Mice Balb/c (Therapeutic, Histologic and Immunologic Study)*. Ph. D. Thesis . College of Science, Kufa University.
5. Al – Mobarak, Z.A. (2006). *Effect of peel extracts of Punica fruits on on echinococcosis of Echinococcus granulosus* . M. Sc. Thesis, College of Education, Kufa University.Iraq.
6. Al- Nasiri, F.S. (2006). *Biological and immunological study of hydatid cyst formation in albino mice*. Ph.D. Thesis, College of Education, University of Baghdad. Iraq.



7. Ahmadinejad, M., Hashemi, M., & Azizallahi, N. (2020). Evaluation of Prognostic Factors Associated with Postoperative Complications Following Pulmonary Hydatid Cyst Surgery. *The open respiratory medicine journal*, 14, 16–21.
8. Ahlberg, V. (2012) Echinococcus multilocularis immuno-modulatory strategies in the intermediate host. *Vet.Program.*, 71:1-10
9. Abdul Rasool, Y.A., AL-Taie, L.H., Husain, H.A. (2012). Serovalue of hydatid disease in Baghdad. *JFac Medical Bagdad*, 54(1), 47-50.
10. AL-Shanawi, F.A., Baker, N.N. & Ibrahim, A.Q. (2012). Study the effect of the mixture aquatic extract of Peganum harmala seeds and Pericarp of Punica granatum on viability of protoscolices of Echinococcus granulosus in vitro and in vivo. *Baghdad Scientis journal*; 9(2):6-20.
11. Chandrasekhar, S., & Parija, S. C. (2009). Serum antibody & Th2 cytokine profiles in patients with cystic echinococcosis. *The Indian journal of medical research*, 130(6), 731–735.
12. Dorosti, Z., Tolouei, S., Khanahmad, H., Jafari, R., Jafae, F., Sharafi, S. M., & Darani, H. Y. (2016). IL-4 gene expression in adventitial layer (fibrous layer) of hepatic ovine and bovine hydatid cysts. *Journal of parasitic diseases: official organ of the Indian Society for Parasitology*, 40(3), 855–859.
13. Gannavaram, S., Bhattacharya, P., Ismail, N., Kaul, A., Singh, R., & Nakhasi, H. L. (2016). Modulation of Innate Immune Mechanisms to Enhance Leishmania Vaccine-Induced Immunity: Role of Coinhibitory Molecules. *Frontiers in immunology*, 7, 1-7.
14. Habioglu, A.D., Mert, D., Karaman, N., Togral, G., Ertek, M. (2019). Cystic echinococcosis cases in a tertiary hospital between 2006 and 2016 Turk Hij Den Biyol Derg, 76(4), 46-53
15. Hammami, A., Hellara, O., Mnari, W., Loussaief, C., Bedioui, F., Safer, L., Golli, M., Chakroun, M., & Saffar, H. (2015). Unusual presentation of severely disseminated and rapidly progressive hydatid cyst: Malignant hydatidosis. *World journal of hepatology*, 7(3), 633–637.
16. Izadi, J. & Ajami, A. (2006). Biochemical profiles of hydatid cyst fluids of Echinococcus granulosus of human and animal origin (Sheep, Goat, Cattle & Camel). *journal. Animal Veterinal. Advanc.*, 5(7), 574- 577.
17. Jankovic, D., Liu, Z., Gause, W.C. (2001). Th1- and Th2-cell commitment during infectious disease: asymmetry in divergent pathways. *Trends Immunol.* Aug;22(8), 7-50.
18. Maki, K. C., Dicklin, M. R., & Kirkpatrick, C. F. (2021). Saturated fats and cardiovascular health: Current evidence and controversies. *Journal of clinical lipidology*, 15(6), 765–772.
19. Mousavi, S.M., Afgar, A., Mohammadi, M.A., Mortezaei, S., Faridi, A., Sadeghi, B., Fasihi Harandi, M. (2020). Biological and morphological consequences of dsRNA-induced suppression of tetraspanin mRNA in developmental stages of Echinococcus granulosus. *Parasit Vectors*; 13(1), 190-197. doi: 10.1186/s13071-020-04052-y. PMID: 32276648; PMCID: PMC7146954.
20. Mezioug, D., & Touil-Boukoffa, C. (2009). Etude du profil cytokinique de patients atteints d'hydatidose: une possible application en matière d'immunosurveillance [Cytokine profile in human hydatidosis: possible role in the immunosurveillance of patients infected with Echinococcus granulosus]. *Parasite (Paris, France)*, 16(1), 57–64.



21. Moraitaki, P., Roussi, P., Emmanouil, Y., Pechlivanidou, R., Bitsakou, C., Konstantinou, M. & Marosis, K. (2010). Pulmonary echinococcosis presenting as a pulmonary mass with fever and haemoptysis, a case report. *Pneumon. journal.* 23 (2), 180 – 183.
22. Nguyen, D.T. & Diamond, L.W. (2000) . *Diagnostic hematology*. 1st ed. Butter Worth Heinemann, Oxford.
23. Ng T. (1997). Erythrocyte sedimentation rate, plasma viscosity and C-reactive protein in clinical practice. *British journal of hospital medicine*, 58(10), 521–523.
24. Nasrieh, M. A., Abdel-Hafez, S. K., Kamhawi, S. A., Craig, P. S., & Schantz, P. M. (2003). Cystic echinococcosis in Jordan: socioeconomic evaluation and risk factors. *Parasitology research*, 90(6), 456–466.
25. Pakala, T., Molina, M., & Wu, G. Y. (2016). Hepatic Echinococcal Cysts: A Review. *Journal of clinical and translational hepatology*, 4(1), 39–46.
26. Rostami-Rad, S., Jafari, R., & Yousofi Darani, H. (2018). Th1/Th2-type cytokine profile in C57 black mice inoculated with live *Echinococcus granulosus* protoscolices. *Journal of infection and public health*, 11(6), 834–839.
27. Refik, M., Mehmet, N., & Durmaz, R. (2005). Postoperative changes in serum cytokines profile and nitric oxide levels in patients with cystic echinococcosis. *Parasite (Paris, France)*, 12(3), 265–269.
28. Roming T. (2003). Epidemiology of echinococcosis. *Langenbeck's archives of surgery*, 388(4), 209–217.
29. Siracusano, A., Delunardo, F., Teggi, A., & Ortona, E. (2012). Host-parasite relationship in cystic echinococcosis: an evolving story. *Clinical & developmental immunology*, 13(9), 63–93.
30. Salama, A.A., Othman, A.A., Zayed, H.A. (2014). Cystic echinococcosis in the middle region of the Nile Delta, Egypt: Clinical and radiological characteristics. *Egyptian Journal Rad Nuclear Medicine* , 45(3): 9-41.
31. Schumann, G., Bonora, R., Ceriotti, F., Férard, G., Ferrero, C. A., Franck, P. F., Gella, F. J., Hoelzel, W., Jørgensen, P. J., Kanno, T., Kessner, A., Klauke, R., Kristiansen, N., Lessinger, J. M., Linsinger, T. P., Misaki, H., Panteghini, M., Pauwels, J., Schiele, F., Schimmel, H. G., (2002). International Federation of Clinical Chemistry and Laboratory Medicine IFCC primary reference procedures for the measurement of catalytic activity concentrations of enzymes at 37 degrees C. International Federation of Clinical Chemistry and Laboratory Medicine. Part 5. Reference procedure for the measurement of catalytic concentration of aspartate aminotransferase. *Clinical chemistry and laboratory medicine*, 40(7), 725–733.
32. Sura, B. K., S. (2013). A Study of Some Biochemical Changes in Hydatid Cyst Patients Before And After Surgical removal of hydatid cyst. *Al Mustansiriyah Journal of Pharmaceutical Sciences*, 13(2), 103–108.
33. Shindala, N. A., Al-Kassim, K. H., Shabaan, E. K., Shehab, A. K., Husain, A. K. , & Alias, H. Y. (2007). *Study the toxic effect of albendazole excretion in the milk on the sucking pups*. The 4th Scientific Conference. College of Veterinary Medicine, Mosul University., 1, 177-188.
34. Torcal, J., Navarro-Zorraquino, M., Lozano, R., Larrad, L., Salinas, J. C., Ferrer, J., Roman, J., & Pastor, C. (1996). Immune response and in vivo production of cytokines in patients with liver hydatidosis. *Clinical and experimental immunology*, 106(2), 317–322.



35. Tishkowski, K., & Gupta, V. (2023). *Erythrocyte Sedimentation Rate. Laboratory hematology practice*, Publishing.638-646.
36. Yakhchali, M., Asri-Rezaie, S., Samimirad, S., & Rezaie, H. (2017). The enzymes and electrolytes profiles in hydatid cyst fluid of naturally infected Iranian domestic ruminants. *Journal of parasitic diseases: official organ of the Indian Society for Parasitology*, 41(4), 1098–1101.
37. Zhang, W., Zhang, Z., Wu, W., Shi, B., Li, J., Zhou, X., Wen, H., & McManus, D. P. (2015). Epidemiology and control of echinococcosis in central Asia, with particular reference to the People's Republic of China. *Acta tropica*, 141, 235–243.